

Abdominal Lump: A Diagnostic Dilemma

Bhandari RS,¹ Shrestha M,² Shrestha GK,³ Mishra PR,⁴ Singh KP⁴

¹Department of surgery, Tribhuvan University Teaching Hospital, Kathmandu, Nepal

ABSTRACT

Abdomen is a Pandora's Box. During our routine patient evaluation we come across different types of abdominal lumps out of which some are straight forward and diagnosed after routine clinical examinations and available investigations. At times these abdominal lumps present differently from their usual presentations and create confusions despite undergoing necessary investigations. The truth is explored only after opening the Pandora's Box. We present a case of 21 years old male who presented with history of gradually increasing right sided upper abdominal lump of three years duration. He was thoroughly investigated with USG and CT scan abdomen along with other supportive investigations and was diagnosed to have Hydatid cyst of liver. Accordingly patient was prepared for surgery and it was only at the time of laparotomy that he was found to have right sided giant hydronephrosis with a nonviable renal parenchymal tissue. He underwent right sided nephrectomy and had a good postoperative recovery. So at times the abdominal lumps keep on creating diagnostic dilemmas.

Key words: abdominal lump, giant hydronephrosis

INTRODUCTION

Although hydronephrotic kidney is a frequently presenting clinical condition, Giant Hydronephrosis is an uncommon entity in adult.¹ The definition of Giant hydronephrosis has been given as the adult renal pelvis containing one liter of urine or 1.6% of body weight.^{2,3} The condition is usually secondary to ureteropelvic junction obstruction and at times stone diseases, trauma, renal ectopia and ureterovesical junction obstruction can also lead to Giant hydronephrosis.⁴ Many abdominal cystic conditions are differential diagnosis of this condition. In our case Giant hydronephrosis was confused with right sided liver Hydatid cyst.

CASE REPORT

A twenty one year old gentleman presented to us with history of progressively increasing abdominal lump

mainly occupying right lumbar, hypochondrium and epigastric region. He used to have vague abdominal discomfort over the same regions and did not have specific characteristic pain. Patient did not have any history of fever, jaundice, vomiting. Also there was no history of loss of weight and he had maintained a good appetite. Hematemesis and melena was also absent. There were no specific urinary or bowel complaints. Patient did not have any significant past, personal or family history. On general physical examination there were no positive findings and vitals were stable. Abdominal examination revealed huge intra abdominal lump measuring 20 x 15cm, cystic in consistency and occupying right hypochondrium, lumbar, epigastric, crossing significantly the midline and extending to the left side of the abdomen (Figure 1). Other systemic examination were grossly intact.

Correspondence:

Dr. Ramesh Singh Bhandari
Department of surgery
Tribhuvan University Teaching Hospital
Kathmandu, Nepal
E-mail: rameshbhandari2000@yahoo.co.in

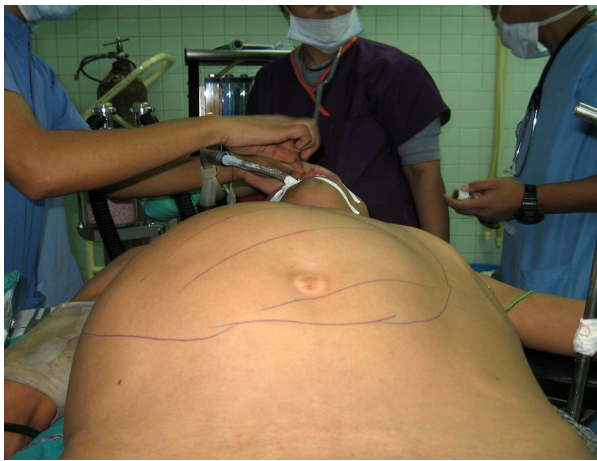

Figure 1. Showing extent of the abdominal lump on examination.

Patient underwent series of various investigations. Routine hematological tests, renal and liver function test were normal. Initially Ultrasound of the abdomen revealed a huge cystic lesion 20x15x15 cm arising from right lobe of the liver with suspicious daughter cyst inside it. So with suspicion of Hydatid cyst, ELISA test for *Echinococcus Granulosus Antibody* was done and it was positive. So there was strong suspicion of Hydatid cyst of liver. Then, CT scan of the abdomen was planned for detailed evaluation of the cyst. It revealed a unilocular cyst arising from the liver. There was some suspicion of right hydronephrotic kidney. But combining USG abdominal finding, positive serological test and CT abdomen finding working diagnosis of Hydatid cyst involving the right lobe of liver was made and planned for exploration.

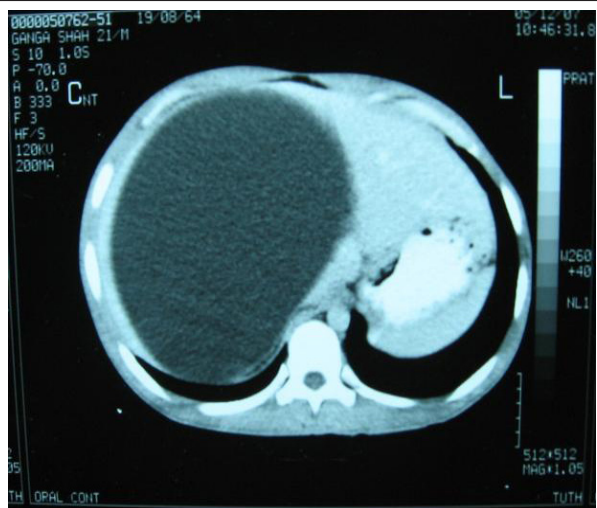

Figure 2. CT abdomen showing cyst arising from the liver.

On exploration through extended right sub costal incision, diagnosis of giant right sided hydronephrotic kidney due

to pelviureteric junction obstruction was made (figure 3). The amount of urine present in the hydronephrotic sac was around 3 liters. The renal parenchymal tissue was atrophied. Thus patient underwent Right sided nephrectomy. Patient had good postoperative outcome and was discharged on 8th postoperative day. Patient has been coming on regular follow up.

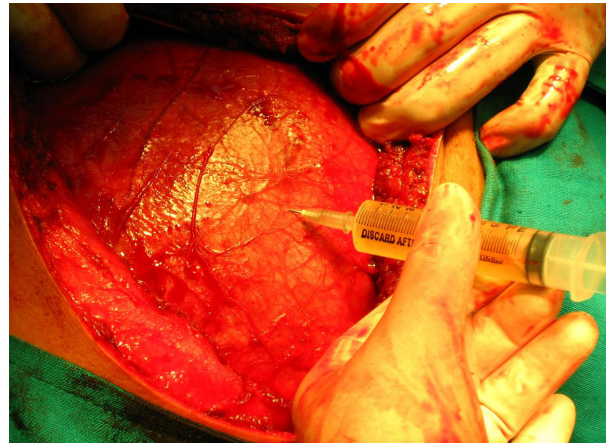


Figure 3. Showing hydronephrotic kidney.

DISCUSSION

Giant hydronephrosis is a rare entity encountered both in adults and children.¹ It has been defined as when the adult renal pelvis contains more than one liter of urine or more than 1.6% of body weight.³ Pfister *et al* has given a radiographic criteria for diagnosis of this condition which includes: 1. Kidney occupies a hemi abdomen, 2. Meets or crosses the midline and 3. About 5 vertebral bodies in length.⁵

The earliest and the largest hydronephrotic sac, containing 115 litres of fluid, was recorded by Glass (1746) in an autopsy report on a 22 year old woman.⁶ Tombari *et al* (1968) reported the second largest case of giant hydronephrosis (52 litres) and reviewed 61 cases in the literature. They found out that out of 61 cases, an erroneous diagnosis was made in 33 cases (54%) and paracentesis was done in 12 cases (20%) because of the initial diagnosis of ascites.⁷

Commonest cause of this clinical condition both in adult and children is congenital ureteropelvic junction (UPJ) obstruction. Occasionally, it can occur as a result of ureterovesical junction obstruction.<http://www.indianjurol.com/article.asp?issn=0970-1591;year=2004;volume=20;issue=2;spage=118;epage=122;aulast=Shah-ref3#ref3> Other causes include obstructive megaureter, ureteric atresia and obstructive ectopic ureter with or without a duplex system. Kruger (1993) reported a case of giant hydronephrosis caused by an impacted ureteric stone on the right side.⁸

Giant hydronephrosis can present with different symptoms like flank pain and hematuria, recurrent urinary tract infections, renal insufficiency if bilateral.⁴ Many at times, patient remain asymptomatic till late stages as the condition progresses slowly.^{4, 9} Since giant hydronephrosis is a slowly increasing disease, a large abdominal mass or distended abdomen may be the only sign and this can be very confusing with many cystic abdominal conditions like hepatobiliary cysts, mesenteric cysts, pseudomyxoma, renal tumor, retroperitoneal tumors, ovarian cyst, retroperitoneal haematoma, ascites and splenomegaly.^{4,9} In our case it was confused with Hydatid cyst of liver. At times accurate diagnosis of giant hydronephrosis in individual cases remains challenging. Diagnosis of this condition is usually done by USG, Excretory, Antegrade and Retrograde urography. CT abdomen is required for ruling out other differential diagnosis.⁴ In our case in spite of doing a CT scan abdomen, diagnosis was still confusing.

All patients with giant hydronephrosis do not have similar anatomical configuration and functional status of renal units, and therefore treatment has to be individualized in every patient.⁴ Usually a strategic approach is followed for treatment of giant hydronephrosis. Initially a percutaneous nephrostomy is done if patient is febrile and/or serum creatinine is elevated or IVU shows non-visualized unit or pelvicalyceal system is not well delineated. Further, based upon overall functional status, ablation of unit or reconstructive surgery is planned.⁴ The type of reconstruction is individualized as per anatomical configuration demonstrated on

antegrade study or IVU. Calyccystostomy and Boari flap calyccovesicostomy have been recommended in cases with massive calyceal dilatation and severely compromised peristalsis in the collecting system.^{10, 11} Hemal et al (1998) studied the role of nephroplication and nephropexy as an adjunct to primary surgery in 20 renal units of 16 patients with giant hydronephrosis.¹² Nephropexy reduces stasis and improves dependent drainage by tilting the pelvicalyceal system laterally and bringing it more in line with the upper ureter. Levitt et al (1981) performed 15 calyccouretostomies as the primary treatment for UPJ obstruction when the dilated lower pole calyx was actually the most dependent portion in a dilated intrarenal collecting system.¹³ They pointed out that in cases of massive calyceal dilatation, peristaltic activity in the collecting system is seriously compromised and urinary drainage from the pelvis into the upper ureter is essentially by gravity. For nonviable kidneys, nephrectomy is the choice. In 1999, Hemal et al reported 18 laparoscopic nephrectomy done for giant hydronephrosis.¹⁴

Despite our best efforts with available investigations, abdominal lumps keep on creating diagnostic dilemmas. Giant hydronephrosis is an uncommon cause of huge intraabdominal swelling and should be kept in differential diagnosis of intraabdominal cystic mass. It usually presents with vague clinical symptoms mimicking a variety of cystic lesions. In very poorly functioning unit with gross infection, nephrectomy is the procedure of choice. If functional unit is salvageable, the type of reconstructive procedure is selected based upon the anatomical configuration.

REFERENCES

1. Yilmaz E, Guney S. Giant Hydronephrosis due to ureteropelvic junction obstruction in a child. CT and MR appearances. *Clin Imaging* **2002**; 26: 125- 128.
2. Chiang PH, Chen MT, Chou YH, Chiang CP, Huang CH, Chien CH. Giant Hydronephrosis: report of 4 cases with review of the literature. *J Formas Med Assoc* **1990**; 89: 811- 817.
3. Earlham MS. Giant Hydronephrosis. *J Urol* **1950**. 63: 195
4. Shah S A, Ranka P, Dodiya S, Jain R, Kadam G. Giant hydronephrosis: What is the ideal treatment? *Indian journal of urology* **2004**; 20: 118- 122
5. Crooks K., Hendren H., Pfister R. Giant Hydronephrosis in Children. *JPed Surg* **1979**. 14(6): 844-850
6. Glass S. Cited by PJ Dennehy. Giant hydronephrosis in a double kidney. *Br J Urol* **1953**; 25: 247-51
7. Tombari AA, Power RF, Harper JM, Politano VA. Giant hydronephrosis: a case report with review of literature. *J Urol* **1968**. 100 (2): 100-20.
8. <http://www.indianjurol.com/article.asp?issn=0970-1591;year=2004;volume=20;issue=2;spage=118;epage=122;aulast=Shah-ft78>. Kruger E. Giant hydronephrosis and contralateral ureteric bud. Problem of differential diagnosis. *Urologe A* **1993**. 32: 316-9.
9. Yapanoglu T et al. Giant hydronephrosis mimicking an intraabdominal mass. *Turk J Med Sci* **2007**; 37(3): 177- 199
10. <http://www.indianjurol.com/article.asp?issn=0970-1591;year=2004;volume=20;issue=2;spage=118;epage=122;aulast=Shah-ft5> Krzeski T, Milewski JB, Borkowski A et al. Calyccystostomy in the treatment of giant hydronephrosis. *Eur Urol* **1987**. 13: 42.
11. Kumar A, Sharma SK, Madhusoodan P, Dhar ML. Indications for Boari flap calyccovesicostomy. *Br J Urol* **1988**; 60: 367-8.
12. Hemal AK, Aron M, Wadhwa SN. Nephroplication and nephropexy as an adjunct to primary surgery in the management of giant hydronephrosis. *J Urol* **1998**. 81: 673-7.
13. Levitt SB, Nabizadeh I, Javaid M, Barr M, Kogan SJ, Hanna MK et al. Primary calyccouretostomy for pelviureteral junction obstruction. Indications and results. *J Urol* **1998**. 126: 382-6.
14. Hemal AK, Wadhwa SN, Kumar M, Gupta NP. Transperitoneal and retroperitoneal laparoscopic nephrectomy for giant hydronephrosis. *J Urol* **1999**. 162: 35-9