



## Scleral Fixation of Intraocular Lens with Ab Interno Technique

Nanda Kumari Gurung,<sup>1</sup> Roshija Rijal,<sup>1</sup> Bel Bahadur Thapa,<sup>1</sup> Shanti Gurung<sup>1</sup>

<sup>1</sup>Department of Glaucoma, Lumbini Eye Institute, Bhairahawa, Nepal.

### ABSTRACT

**Introduction:** Implantation of scleral fixation intraocular lens for the surgical management of aphakia cases without capsular support is a safe procedure.

**Methods:** Prospective study was carried out at Lumbini Eye Institute, Bhairahawa. A total of 32 patients underwent scleral fixation intraocular lens implantation within a period of two years from February 2014 to February 2016.

**Results:** The age range was from 15 to 79 years; mean age was  $47.56 \pm 20.16$  SD. Among them 14 (43.75%) were male and 18 (56.25%) were female. The follow-up lasted for 24 months.

**Conclusions:** SFIOL for the surgical management of aphakia in the absence of capsular support is a safe procedure. The long-term follow-up is needed for an accurate evaluation of outcomes.

**Keywords:** *double armed prolene suture; intraocular pressure; scleral fixation intraocular lens; scleral tunnel.*

### INTRODUCTION

In ab interno fixation, the suture is passed from the inside to the outside of the eye in order to avoid the blind pass through the ciliary sulcus.<sup>1</sup> Implantation of a scleral-fixed intraocular lens for the surgical management of aphakia in the absence of capsular support is a safe procedure with a low risk of complications in the early postoperative period.<sup>2</sup>

This technique of suture knot coverage was described in 2006 by Hoffman, et al,<sup>3,4</sup> and avoids the need for conjunctival dissection, scleral cauterization and the complication like scleral wound and its infection due to exposed suture.

This study aims to see the advantage of scleral fixation of intraocular lens with ab Interno Technique over the ab Externo Technique.

### METHODS

A hospital based prospective observational study was carried out in Lumbini Eye Institute, Bhairahawa. Ethical approval was taken from Institutional Review Board (IRB) of Lumbini Eye Institute, Bhairahawa. All subjects were randomly selected. Primary and secondary aphakia patients within a period of two years from February 2014 - February 2016 were enrolled after a verbal/written informed consent. Data analysis was performed using the statistical software SPSS Version 16. Data were analyzed by the Mann Whitney U test, paired t-tests and descriptive analysis.

Demographic assessments like name, age, gender, address and occupation were evaluated. A brief

**Correspondence:** Dr. Nanda Kumari Gurung, Department of Glaucoma, Lumbini Eye Institute, Bhairahawa, Nepal. Email: gurun55@yahoo.com, Phone: +977-9847031486.

personal history, medical history, anti-glaucoma drug history, history of cataract surgery, complication, iris status, history of ocular trauma and family history were also taken. All patients underwent full ophthalmological examination, including best corrected visual acuity, slit lamp bio-microscopy, B scan, anterior chamber depth, Goldmann applanation, central corneal thickness and gonioscopy. Fundus examination was performed with 90D lens.

The patients were divided into groups according to their clinical presentation and the nature of the procedure required.<sup>5,13</sup> Primary scleral fixation of IOL included: patients who had capsular rupture during planned extra capsular cataract extraction and patients presenting with subluxated crystalline lens or dislocated lens. Secondary scleral fixation of IOL included patients wanting secondary implantation of IOL in aphakic eyes lack of posterior capsular support. Miscellaneous included trabeculectomy combined with scleral fixation of IOL and intraocular lens exchange procedures patient having anterior chamber IOL. The patients with diabetic retinopathy, high myopia, aniridia, glaucoma and chronic uveitis were excluded in the study.

All surgeries were performed under peribulbar anesthesia by the same surgeon of Lumbini Eye Institute. A small conjunctival periotomy overlying the region for scleral dissection was performed. Bipolar cautery was used if needed. Calipers and markers were used to mark the size of the scleral pocket. The pockets were created 180 degrees from each other, avoiding the long posterior ciliary arteries at the 3 O'clock and 9 O'clock meridians. A 3.0 mm partial thickness scleral incision was made posterior to the surgical limbus with a crescent blade.<sup>6</sup> The tunnels were created at 8:30 o'clock and 2:30 O'clock meridians. The pocket was extended to the limbus without penetrating the anterior chamber. Paracentesis was done in the clear cornea with a 15 degree MVR blade at the 10 O'clock position. Scleral tunnel was created at the 12 O'clock position like a Small Incision Cataract Surgery (SICS). Anterior vitrectomy was performed as a routine accompaniment. A double armed 10.0 prolene suture on straight needle was passed through partial thickness scleral tunnel from one side and hollow 27 gauge needle was passed from other side. Transscleral suture passage was performed with ab interno technique.<sup>7</sup> Docking of 10.0 prolene suture was done into a 27 gauge hollow needle. A sinskey hook was used to pull out a loop of this suture through the superior tunnel.<sup>7</sup> Pulling the trailing suture end through external excision and cut into two, each end of the suture was tied with IOL haptic. The IOL was placed in the eye. Suture was gently pulled to secure the position of the SFIOL. Cinching and tying the double-armed suture ends in four point scleral

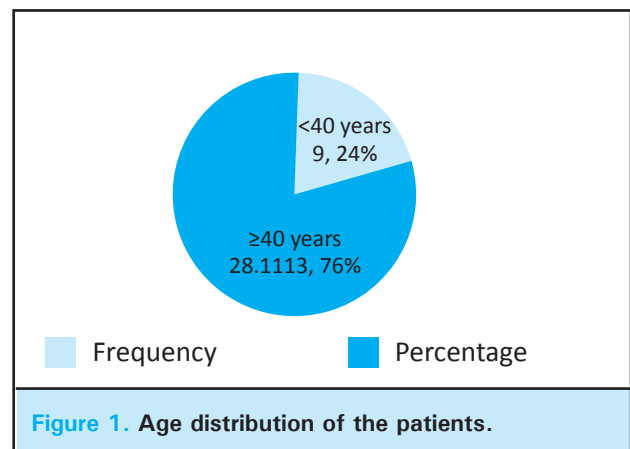
fixation of the IOL haptics and concealment of the knot under the scleral pocket.<sup>8</sup> Suturing the scleral pocket and conjunctival periotomy was not necessary. Scleral incision was closed with 8.0 vicryl suture if needed. This technique of suture knot coverage was described in 2006 by Hoffman, et al,<sup>4</sup> and avoids the need for conjunctival dissection, scleral cauterization, or scleral wound.<sup>9</sup> Following surgery, intra cameral inj. Cefuroxime 1mg was injected for all cases.

Post operatively, all patients were treated with 1% prednisolone acetate two hourly for two weeks then tapered according to the anterior chamber inflammatory reaction up to 45 days and 0.3% ofloxacin eye drop four times a day. Patients were evaluated on the first postoperative day, 14 days, one month, three months, six months and 12 months. Surgical Outcomes were defined as best corrected visual acuity, SFIOL position, IOP and complications.

## RESULTS

The age range was from 15 to 79 years; mean age was  $47.56 \pm 20.16$  SD. Among them 14 (43.75%) were males and 18 (56.25%) were females. Minimum age was 15 whereas, maximum age was 70 with a mean of 47.56 and SD of 20.17.

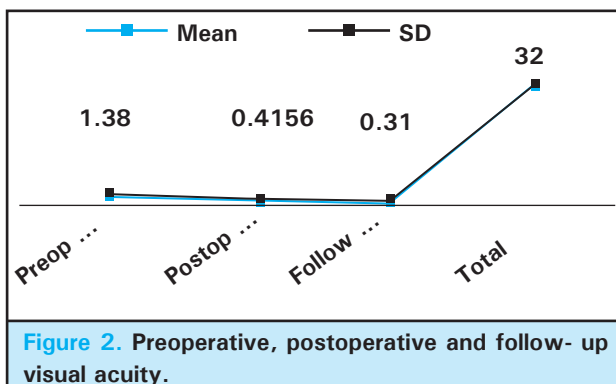
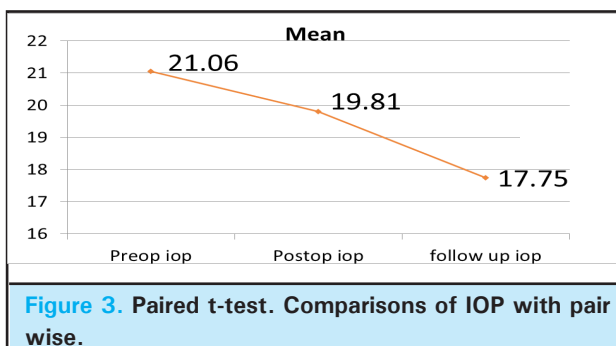
Median values for two groups, interpretation: P values as significant or not significant for median differences among male and female or age <40 and >40 years (Table 1).



**Table 1. Mann Whitney U test.**

Age	<40 Median			≥40 Median			
	n	Q1	Q3	n	Q1	Q3	P
Particulars							
Preoperative IOP	18	14	18	22	18	27	0.002
Postoperative IOP	18	16	20	20	18	24	0.027
Follow-up IOP	16	16	17.5	18	16	20	0.032
Female				Male			
Preoperative IOP	20	16.75	24.5	18	17.75	26.25	0.878
Postoperative IOP	20	18	22.5	20	16	20.5	0.388
Follow-up IOP	16	16	18.5	18	16	20	0.309

*n* = Total number, Q1= First Quartile, Q3 = Third Quartile and P= *p*-value

**Figure 2. Preoperative, postoperative and follow-up visual acuity.****Figure 3. Paired t-test. Comparisons of IOP with pair wise.****Table 2. Descriptive analysis.**

Descriptive statistics	n	Minimum	Maximum	mean	SD
Preop VA	32	0.18	2.08	1.38	0.56
PostOp. VA	32	0	1	0.42	0.24
Follow-up VA	32	0	1.08	0.32	0.22

## DISCUSSION

Options for secondary intraocular lens implantation in an eye lacking capsular support includes anterior chamber

IOL, iris fixation and transscleral fixation through the ciliary sulcus or pars plana.<sup>1-3</sup> Despite renewed interest in iris fixation of secondary IOLs, eye lacking adequate iris tissue for IOL fixation or eyes requiring large aniridia prosthetic lenses necessitate an approach using scleral fixation of the implant. Some authors recommend using larger IOLs for these techniques in order to prevent torsion of the haptics and subsequent scleral erosion or IOL dislocation.<sup>2</sup> However, data on long-term functional outcomes are limited of IOL dislocation.<sup>3</sup> Scleral fixation of intraocular lens and adjunctive capsular devices can also be performed under the protection of a scleral flap.

The techniques for transscleral fixation of secondary IOLs have underwent many modifications and improvements over the past two decades.<sup>5</sup> Transillumination technique<sup>10</sup> for locating the ciliary sulcus for suturing a posterior chamber intraocular lens can be performed. Transscleral illumination with a light-guide fiber placed underneath the iris reveals the ciliary sulcus as a bright area near the limbus. It allows for a straight needle with 10-0 polypropylene fiber to be easily inserted through the sulcus after making two pairs of radial scleral incisions to fixate the 10-0 polypropylene fiber.

Intraocular lens tilt can be improved using a technique that results from a single pass through the sclera.<sup>11</sup> Late IOL dislocation, resulting from mechanism of 10-0 prolene suture degradation, may be reduced by ensuring more accurate placement of haptics within the ciliary sulcus by using a thicker suture such as 9-0 prolene or 8-0 Gore-Tex.<sup>5,12</sup> Transscleral suture posterior chamber IOL is technically difficult. It avoids complication with anterior chamber IOL implantation, such as corneal endothelial decompensation, uveitis-glaucoma-hypema syndrome and cystoid macular edema. Tilting and decentration of transscleral sutured posterior chamber IOL can lead to breakage of the polypropylene sutures.

It is the most common late post operative complication requiring a reoperation.<sup>13</sup> The ability to retrieve the suture ends through the external incision of the tunnel which facilitates the initial suture. Pass of an ab interno approach is aided in similar manner by the ability to accurately pass the docking needle through the external sclera at the desired distance from the limbus without lifting the roof, which is necessary if the docking needle is passed through the external incision opening. Once each true end is retrieved through the external opening tying the two ends with a surgeon's knot, it will protect the tunnel roof. Suturing the tunnel is not required.<sup>14</sup> This modification of the traditional scleral flap simplifies the creation of a scleral covering, eliminating the need to rotate suture knots while facilitating needle placement for an ab interno technique.<sup>15</sup>

Limitation of this study was unavailability of Ultrasound Bimicroscopy which is needed to evaluate the accurate

position of the IOL during follow-up visits. Also, skilled ophthalmologists are required to perform this type of surgery.

## CONCLUSIONS

Implantation of a SFIOL for the surgical management of aphakia in the absence of capsular support is a safe procedure with a low risk of complications in the early post operative stages. The scleral pocket technique performed in this study prevented the exposure of the suture knots and hence its related complications. A long-term follow up is recommended for accurate outcomes.

## ACKNOWLEDGEMENTS

We would like to thank Ms. Aayusha Gajurel and Ms. Leepy Paudel for their valuable contribution during this study.

## REFERENCES

1. EyeWiki RG, et al. Scleral fixated intraocular lens. *Ophthalmol.* 2003;110:840-59. [\[Full Text\]](#)
2. Zia ul Mazhri, Wasif M Qadri. Scleral Fixation of Intraocular Lens. *Pak J Ophthalmol J.* 2008;24(4):184-92. [\[Full Text\]](#)
3. Hoffman RS, Fine H, Packer M. Scleral fixation without conjunctival dissection. *J Cataract Refract Surg.* 2006;32:1907-12. [\[PubMed | DOI\]](#)
4. Hoffman RS, Fine IH, Packer M, et al. Scleral fixation using suture retrieval through a scleral tunnel. *J Cataract Refract Surg.* 2006 Aug;32(8):1259-63. [\[PubMed | DOI\]](#)
5. Khan, et al. Scleral fixation of intraocular lenses using Gore-Tex suture: clinical outcomes and safety profile. *Br J Ophthalmol.* 2016;100:638-43. [\[PubMed | DOI\]](#)
6. Chongde Long, Yantao Wei, Zhaohui Yuan, et al. Modified technique for transscleral fixation of posterior chamber intraocular lenses. *BMC Ophthalmol.* 2015;15:127. [\[DOI | Full Text\]](#)
7. Hoffman RS, Fine H, Packer M, et al. Scleral fixation using suture retrieval through a scleral tunnel. *J Cataract Refract Surg.* 2006;32(8):1259-63. [\[Full Text\]](#)
8. Hoffman RS, Fine H, Packer M, et al. Scleral fixation of intraocular lenses (IOLs) can be performed under the protection of a scleral flap. A variation of this technique uses a scleral tunnel for suture. *J Cataract Refract Surg.* 2006;32:1259-63. [\[Full Text\]](#)
9. Hoffman RS, Fine H, Packer M, et al. Scleral fixation without conjunctival dissection. *J Cataract Refract Surg.* 2006;32:1907-12. [\[PubMed | DOI\]](#)
10. Horiguchi M, Hirotsu H, Koura T, et al. Identifying the ciliary sulcus for suturing a posterior chamber intraocular lens by transillumination. *Arch Ophthalmol.* 1993;111:1693-5. [\[PubMed | Full Text\]](#)
11. Kreshner RM. Simple method of transscleral fixation of a posterior chamber intraocular lens in the absence of lens capsule. *J Cataract Refract Surg.* 1994;10:647-51. [\[PubMed\]](#)
12. Hoffman RS, Fine H, Packer M, et al. Scleral Fixation using suture retrieval through a scleral tunnel. *J Cataract Refract Surg.* 2006;32:1259-63. [\[PubMed | DOI | Full Text\]](#)
13. Shin D, Birt CM, O'Grady JM, et al. Trans scleral suture fixation of posterior chamber lenses combined with trabeculectomy. *Ophthalmol.* 2001;108:919-29 [\[PubMed | Full Text\]](#)
14. Lee JH, Chang JH. Suture to limbal distances in eyes with posterior chamber intraocular lens implanted by scleral fixation. *J Cataract Refract Surg.* 1993 Mar;19(2):278-83. [\[PubMed\]](#)
15. Agapitos PJ, Lindstrom RL. Transscleral ciliary sulcus fixation of posterior chamber intraocular lens implants. *Aust N Z J Ophthalmol.* 1989;17:169-72. [\[PubMed | FULL TEXT\]](#)