

## Primary Osteosarcoma of the Breast

Sushama Bhatta,<sup>1</sup> Gopi Aryal<sup>1</sup>

<sup>1</sup>Department of Pathology, KIST Medical College, Imadol, Lalitpur, Nepal.

### ABSTRACT

Primary extra-osseous osteogenic sarcomas have been reported in many tissues of the body but their occurrence in the breast is rare. The tumor has poor prognosis with high risk of recurrence and hematogenous spread, most commonly to the lungs. We report a case of primary osteosarcoma of the breast occurring in a 58-year old woman. Histo-pathological examination revealed pleomorphic tumor cells with osteoid formation and positivity for immuno-histochemical stain vimentin.

**Keywords:** *breast; histopathology; osteosarcoma.*

### INTRODUCTION

Breast cancer is the commonest cancer that affects females worldwide.<sup>1</sup> However sarcoma of the breast have negligible incidence. The more common breast sarcomas include fibrosarcomas, malignant fibrous histiocytoma, angiosarcoma, and liposarcoma.<sup>1-5</sup> Mammary sarcomas are very uncommon and make up less than 1% of all primary breast malignancies. Primary osteosarcoma of the breast (POB) is extremely rare and represents 12.5% of mammary sarcomas.<sup>3,4</sup> We report a case of POB in a 58-year-old woman.

### CASE REPORT

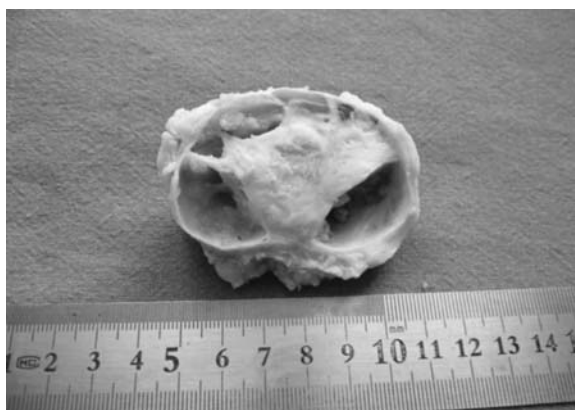
A 58-year-old female presented with a history of right breast lump for 3 months. There was no history of nipple discharge, hormonal treatment or family history of breast cancer. On examination the lump was located in the upper outer quadrant of breast, mobile, not fixed to skin or underlying chest wall. Axillary lymph nodes were not palpable. Chest X-ray was normal. There was no evidence of bony lesion in any other site of

the body on radiological examination. Left breast was unremarkable.

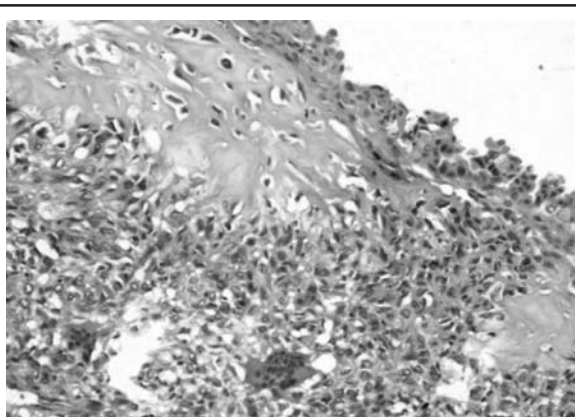
An excisional biopsy of the lump was performed and the specimen was sent for histopathological examination.

The gross specimen showed a well circumscribed lump measuring 6 x 6 x 4 cm. Cut section showed solid and cystic areas (Figure 1). On microscopic examination, solid area was composed of diffuse sheets of polygonal to spindle tumor cells with moderate nuclear pleomorphism. Foci of osteoid production and scattered osteoclast like giant cells were seen (Figure 2). Cyst wall was lined by stratified cuboidal to columnar epithelial cells. Sheets of tumor cells were seen underlying the cyst wall (Figure 3). Immunohistochemically, the neoplastic osteoblastic cells showed positivity for vimentin (Figure 4) but negative for epithelial membrane antigen (EMA).

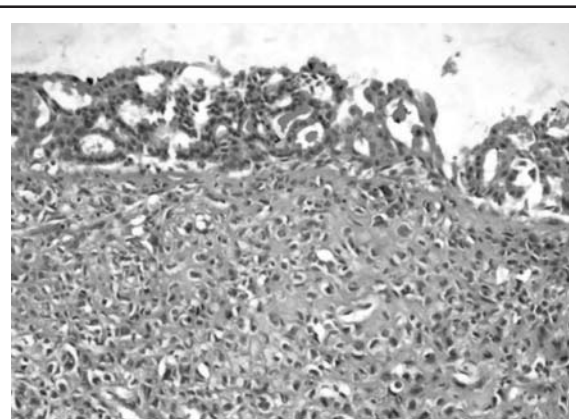
**Correspondence:** Dr. Gopi Aryal, Department of Pathology, KIST Medical College, Lalitpur, Nepal. E-mail: gopiaryal1@gmail.com, Phone: +977-9851102008.



**Figure 1.** Gross photograph showing solid and cystic areas.



**Figure 2.** Tumor cells with osteoid production. Multinucleated giant cells are seen at the bottom. (HE stain x100)




**Figure 3.** Tubular structures lining the cyst wall. Sheets of tumor cells are seen underneath cyst wall. (HE stain x100)

Tubular structures lining the cyst wall. Sheets of tumor cells are seen underneath cyst wall. (HE X100)

## DISCUSSION

Extra-skeletal osteosarcoma has been documented in many tissues of the body including thyroid gland, kidney, bladder, colon, heart, testis, penis, gallbladder and cerebellum but mammary osteogenic sarcomas constitute only a small group.<sup>6</sup> Extra-skeletal osteosarcomas occur in patients over 50 years of age, which is in contrast to osteogenic sarcoma arising from bone which mainly occurs in children and adolescents.<sup>7</sup> POB are very rare and often found in women with a mean age of 64 years. The duration of symptoms is variable but most present within few months. The tumor size ranges from 1.4 to 30 cm with mean of 4.6 cm.<sup>2</sup> The correct diagnosis is established only after surgical resection and histo-pathological examination.<sup>1</sup>



**Figure 4.** Sheets of tumor cells, positive for Vimentin. (Immunohistochemistry for vimentin x100)

POB originates either from normal breast tissue de novo, or as metaplastic differentiation of a primary benign or malignant breast lesion.<sup>1,3</sup> Histologically POB is indistinguishable from conventional osteosarcoma of the bone and other extraskeletal osteosarcoma. Variants like fibroblastic, osteoblastic, osteoclastic (giant cell rich), and chondroblastic have been reported but in all variable amount of osteoid and bone are present.<sup>3</sup> The criteria for diagnosis of POB include exclusion of origin in bone, presence of neoplastic osteoid or bone, absence of an epithelial component and no association with a benign tumor.<sup>8</sup> In addition there should be absence of direct connection between the tumor and the underlying skeleton.<sup>9,10</sup>

The main histological differential diagnosis of primary mammary osteosarcoma is metaplastic carcinoma containing osteoid and bone. This differentiation is important as the histological behavior and management of the two differ.<sup>3</sup> Immunohistochemistry has a major role in diagnosis of POB. Metaplastic carcinoma is immunoreactive for CK, whereas OS is negative. The cells of osteosarcoma display negativity for EMA, ER,

PR, and Her-2, and are vimentin positive; areas of cartilaginous differentiation show S-100 positivity.<sup>2,3</sup> In our case the tumor cells were positive for vimentin and negative for EMA.

Unlike carcinomas, osteosarcoma of the breast rarely metastasizes to lymph nodes. Hence only a wide surgical excision of the tumor without axillary node dissection has been advocated.<sup>2,5</sup> The role of chemotherapy is not well established. It is not recommended in low grade tumors, tumor with no evidence of metastasis and adequate local excision.<sup>7,11</sup> Primary mammary osteosarcoma are highly aggressive

with early recurrence and propensity for hematogenous spread. Metastases are most commonly to lung followed by bone and liver.<sup>12</sup> The 5-year survival rate is 38%. Prognostic factors include tumor size, number of mitoses, and presence of stromal atypia, histological subtype and resection margin involvement.<sup>2</sup>

In conclusion POB are rare malignant tumors. It is important to differentiate these tumors from osteoid/bone-producing metaplastic carcinoma as the two differ in their biological behavior and treatment protocols. Immunohistochemistry has a major role in differentiating these tumors.

## REFERENCES

1. Ogundiran TO, Ademola SA, Oluwatosin OM, Akang EE, Adebamowo CA. Primary osteogenic sarcoma of the breast. *World J Surg Oncol*. 2006;4:90.
2. Silver SA, Tavassoli FA. Primary osteogenic sarcoma of the breast: a clinicopathologic analysis of 50 cases. *Am J Surg Pathol*. 1998;22:925-933.
3. Bahrami A, Resetskova E, Ro JY, Ibanez JD, Ayala AG. Primary osteosarcoma of the breast: report of 2 cases. *Arch Pathol Lab Med*. 2007;131:792-5.
4. Blanchard DK, Reynolds CA, Grant CS, Donohue JH. Primary non-phylloides breast sarcomas. *Am J Surg*. 2003;186:359-61.
5. Ciatto S, Bonardi R, Cataliotti L, Cardona G. Sarcomas of the breast: A multicenter series of 70 cases. *Neoplasma*. 1992;39:375-9.
6. Khaldi L, Athanasiou ET, Hadjitheofilou CT. Primary mammary osteogenic sarcoma. *Histol Histopathol*. 2007;22:373-7.
7. Irshad K, Mann BS, Campbell H. Primary osteosarcoma of the breast. *Breast*. 2003;12:72-4.
8. Murakami S, Isozaki H, Shou T et al. Primary osteosarcoma of the breast. *Pathol Int*. 2009;59:111-5.
9. Momoi H, Wada Y, Sarumaru S, Tamaki N, Gomi T, Kanaya S, Katayama T, Ootoshi M, Fukumoto M. Primary osteosarcoma of the breast. *Breast cancer*. 2004;11:396-400.
10. Ninomiya J, Oyama T, Horiguchi J, Koibuchi Y, Yoshida T, Lijima K, Yoshida M, Takata D, Liny Y, Morishita Y. Two cases of breast cancer with cartilaginous and osseous metaplasia. *Breast cancer*. 2005;12:52-6.
11. Farrugia DC, Rashid AM, Parker MC. Primary osteosarcoma of the breast. *Eur J Surg Oncol*. 1995;21:686-8.
12. Khan S, Griffiths EA, Shah N, Ravi S. Primary osteogenic sarcoma of the breast: A case report. *Cases J*. 2008;1:148.